

# *Hydatigera taeniaeformis* (Cestoda: Taeniidae) in the Yucatán squirrel *Sciurus yucatanensis* (Rodentia: Sciuridae), México

JESÚS ALONSO PANTI-MAY<sup>1\*</sup>, SILVIA F. HERNÁNDEZ-BETANCOURT<sup>2</sup> AND LUIS GARCÍA-PRIETO<sup>3</sup>

<sup>1</sup> Doctorado en Ciencias Agropecuarias, Campus de Ciencias Biológicas y Agropecuarias, Universidad Autónoma de Yucatán, Km 15.5 carretera Mérida-Xmatkuil, CP. 97135, Mérida. Yucatán, México. Email: [panti.alonso@gmail.com](mailto:panti.alonso@gmail.com) (JAPM).

<sup>2</sup> Departamento de Zoología, Campus de Ciencias Biológicas y Agropecuarias, Universidad Autónoma de Yucatán, Km 15.5 carretera Mérida-Xmatkuil, CP. 97135, Mérida. Yucatán, México. Email: [hbetanc@correo.uady.mx](mailto:hbetanc@correo.uady.mx) (SFHB).

<sup>3</sup> Colección Nacional de Helmintos, Instituto de Biología, Universidad Nacional Autónoma de México, Ciudad Universitaria, CP. 04510, Ciudad de México. México. Email: [luis.garcia@ib.unam.mx](mailto:luis.garcia@ib.unam.mx) (LGP).

\*Corresponding author

The present study reports for the first time the occurrence of *Hydatigera taeniaeformis* (Cestoda: Taeniidae) in the Yucatán squirrel *Sciurus yucatanensis* (Rodentia: Sciuridae) in Yucatán, México. Thirty larval stages of cestodes were collected in the liver and mesenteries of an adult male squirrel. This study increases to 11 the total number of helminth taxa known from squirrels in México.

El presente estudio reporta por primera vez la presencia de *Hydatigera taeniaeformis* (Cestoda: Taeniidae) en la ardilla de Yucatán *Sciurus yucatanensis* (Rodentia: Sciuridae) en Yucatán, México. Treinta estados larvales de cestodos fueron colectados del hígado y mesenterios de una ardilla macho adulta. Este estudio incrementa a 11 el número total de taxa de helmintos conocidas en ardillas en México.

**Key words:** Cestode; infection; rodent; Yucatán peninsula.

© 2019 Asociación Mexicana de Mastozoología, [www.mastozoologiamexicana.org](http://www.mastozoologiamexicana.org)

## Introduction

Adult cestodes of the genus *Hydatigera* Lamarck 1816 are intestinal parasites of felid or viverrid mammals and develop as larval stages or metacestodes in tissues and body cavities of their intermediate hosts (rodents; [Lavikainen et al. 2016](#)). The genus consists of four valid species: *Hydatigera taeniaeformis* (Batsch 1786), *Hydatigera krepkogorski* Schulz and Landa 1934, *Hydatigera parva* (Baer 1924), and *Hydatigera kamiyai* Lavikainen et al. 2016. *Hydatigera taeniaeformis* is the most common cestode parasitizing the small intestine of the domestic cat *Felis catus* and other wild felids ([Jones and Pybus 2001](#)). The life cycle of this cestode includes several rodent species as intermediate hosts, in which the strobilocercus usually develops in the liver. Although, *H. taeniaeformis* has a wide range of hosts, most studies have recorded it in domestic cats and synanthropic rodents, such as *Mus musculus*, *Rattus rattus*, and *Rattus norvegicus* ([Lavikainen et al. 2016](#)). A recent molecular study of specimens of *H. taeniaeformis* from Asia, Europe and Africa revealed the occurrence of cryptic species, resulting in the splitting of the species in three lineages: *H. taeniaeformis sensu stricto*, the recently discovered *H. kamiyai* and an undescribed species or an intraspecific variant, *Hydatigera* sp. ([Lavikainen et al. 2016](#)).

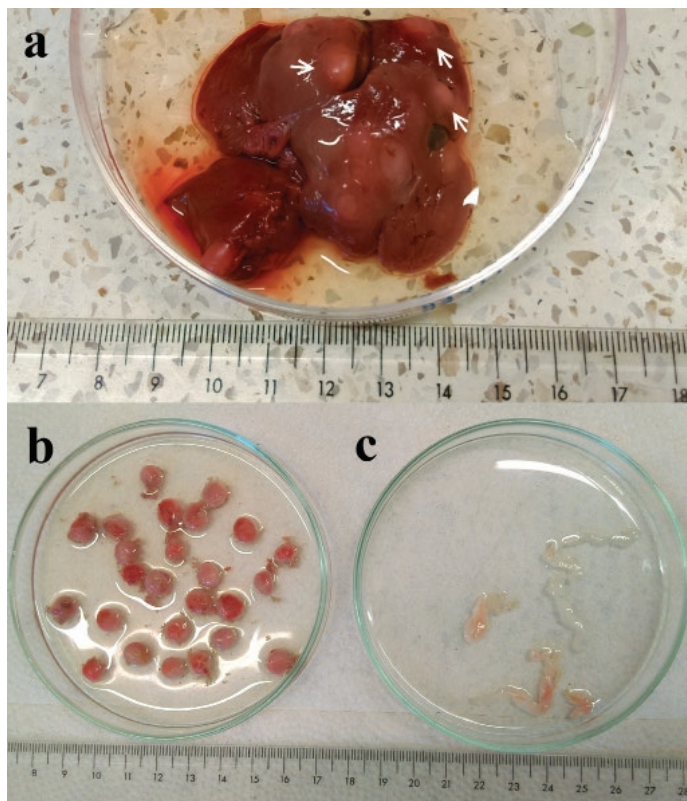
In México, there are records of *H. taeniaeformis* in domestic cats ([Pacheco-Coronel 2010](#); [Cantó et al. 2013](#)) and synanthropic rodents ([Caballero y Caballero 1939](#); [Hierro-Huerta 1992](#); [Pulido-Flores et al. 2005](#); [Rodríguez-Vivas et al. 2011](#); [Panti-May et al. 2015, 2017, 2018](#)). However, there are few records of its occurrence in wild mammals. In the present work, we report for the first time the infection with *H. taeniaeformis* in the Yucatán squirrel *Sciurus yucatanensis* in the State of Yucatán, México.

On 1 May 2018, an adult male of *S. yucatanensis* was found run over by a car on the outskirts of Ebtún (20° 39' 50.18" N, -88° 15' 50.47" W), Valladolid, Yucatán. The specimen was collected for parasitological studies. At the laboratory, heart, lungs, gastrointestinal tract (from stomach to rectum), pancreas, liver and mesenteries, were dissected and examined for helminths using a stereoscope. We only found cysts containing larval stages of cestodes in the liver and mesenteries of the squirrel. Larval stages were studied with the aid of an optic microscope and a scanning electron microscopy (SEM). Drawings of rostellar hooks were made with the aid of micrographs taken with an optic microscope (Olympus IX81). For SEM micrographs, specimens were dehydrated using graded ethanol series and critical-point dried with carbon dioxide. Dry specimens were mounted on metal stubs, coated with a gold-palladium mixture and examined with a SEM (Hitachi SU1510). Total genomic DNA of one specimen of *H. taeniaeformis* was extracted using DNeasy Blood and Tissue Kit (QIAGEN, Hilden, Germany), following the manufacturer's instructions. The D1-D3 region of the 28S rRNA gene was amplified using the polymerase chain reaction (PCR). The use of primers for PCR amplification, the thermo-cycling profile, and sequencing followed the protocols described by [Hernández-Mena et al. \(2017\)](#). The resulting sequences were assembled in Geneious Pro 4.8.4 (Biomatters Ltd.) to obtain a consensus sequence. The sequence was submitted to GenBank with the accession number MK514275. The host specimen was deposited in the Colección Mastozoológica (CM), Campus de Ciencias Biológicas y Agropecuarias, Universidad Autónoma de Yucatán (CM-1300), and helminth specimens fixed in ethanol were deposited in the Colección Nacional

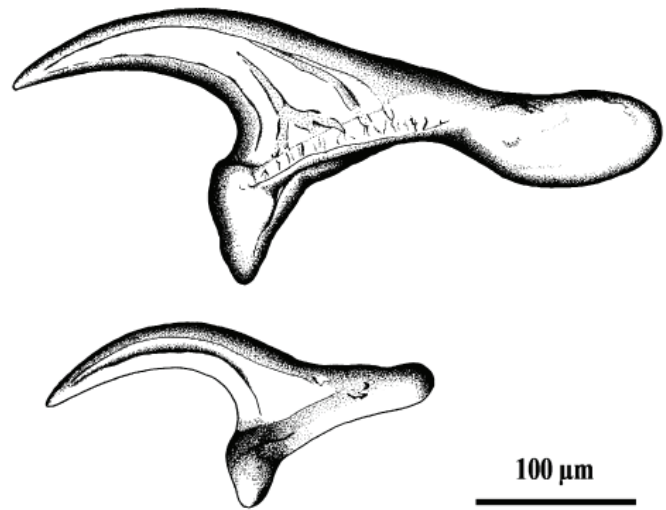
de Helminthos (CNHE), Instituto de Biología, Universidad Nacional Autónoma de México, México City (CNHE 10927).

Thirty cysts were collected, 29 in the liver and one in the mesenteries. Each cyst contained one larval stage, which measured from 5 to 130  $\mu\text{m}$  (Figure 1a to c). The cestode specimens showed the diagnostic characteristics of the genus *Hydatigera* (i. e., large rostellar hooks and metacercodes as strobilocercus with prominent segmented strobilae; Lavikainen et al. 2016; Catalano et al. 2019). The general characteristics of all strobilocerci found, such as scolex with four suckers of 223  $\mu\text{m}$  length by 120  $\mu\text{m}$  wide; rostellum with double alternative crowns of 17 to 20 hooks each; longer hooks 368 to 409  $\mu\text{m}$  in length and smaller hooks 224 to 246  $\mu\text{m}$  in length (Figures 2, 3), were in accordance with descriptions of *H. taeniaeformis* given by Dobrovolny and Harbaugh (1934), Lavikainen et al. (2016), Panti-May et al. (2018). On the other hand, the newly generated sequence of the nuclear 28S rRNA gene was compared with other sequences available in GenBank through the BLASTn algorithm ([https://blast.ncbi.nlm.nih.gov/Blast.cgi?PAGE\\_TYPE=BlastSearch](https://blast.ncbi.nlm.nih.gov/Blast.cgi?PAGE_TYPE=BlastSearch)), and allowed us to associate our sequence with *H. taeniaeformis sensu stricto* isolated from *R. norvegicus* (Genbank accession number: JN020350) and from *R. rattus* (JN020349) in India, with identity percentages of 100 % and 99.4 %, respectively.

In México, larval stages of *H. taeniaeformis* have been found in the liver of several rodent species. It has been recorded from *M. musculus* in México City (García-Prieto et al. 2012) and Yucatán (Rodríguez-Vivas et al. 2011; Panti-



**Figure 1.** *Hydatigera taeniaeformis* collected from the liver of *Sciurus yucatanensis*. a) *H. taeniaeformis* cysts (arrows) into the liver of *S. yucatanensis*. b) Hepatic cysts. c) Larval stages of *H. taeniaeformis*. Scale in centimeters.

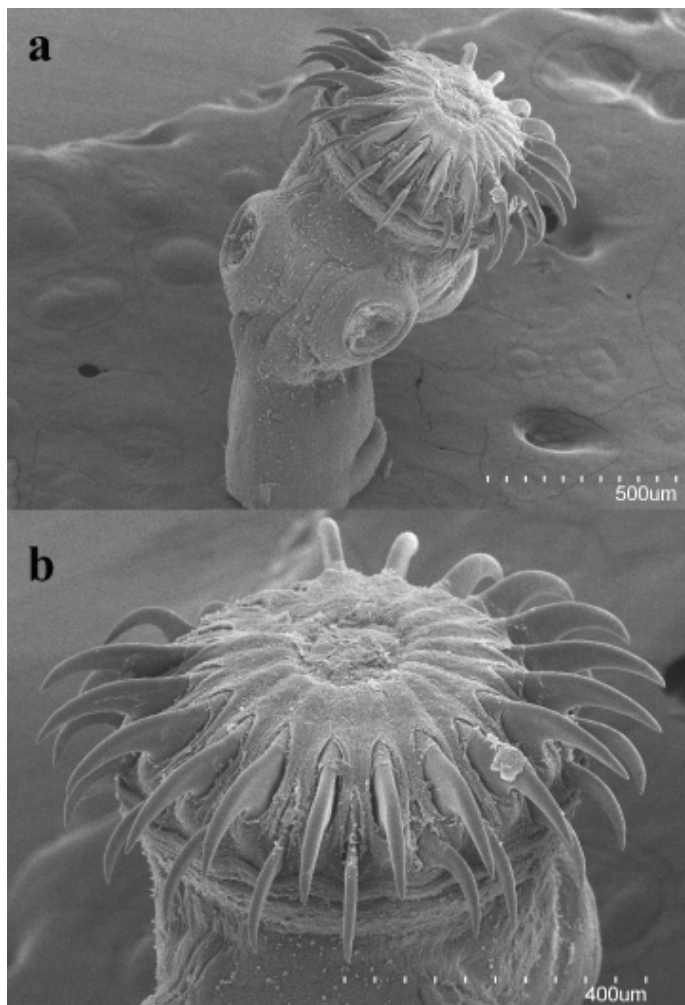


**Figure 2.** Drawings of large and small rostellar hooks of larvae of *Hydatigera taeniaeformis*.

May et al. 2015, 2017, 2018), *R. rattus* in Hidalgo (Pulido-Flores et al. 2005) and Yucatán (Rodríguez-Vivas et al. 2011; Panti-May et al. 2015, 2017, 2018), and *R. norvegicus* in México City (Caballero y Caballero 1939) and Michoacán (Hierro-Huerta 1992). In wild rodents, records have been made from *Sigmodon hispidus* in Nuevo León (Gutiérrez-González 1980) and *Sigmodon toltecus* in Yucatán (Panti-May et al. 2018). Adult worms of *H. taeniaeformis* have been collected from the intestines of feral and domestic cats in México City (Pacheco-Coronel 2010) and Queretaro (Cantó et al. 2013), respectively.

In this study we report for the first time the natural infection of a squirrel with *H. taeniaeformis* in México. In the Americas, there are few reports on the infection of *H. taeniaeformis* in squirrels. In the United States, the red squirrel *Sciurus niger rufiventer* (Dobrovolny and Harbaugh 1934; Rausch and Tiner 1948) and the gray squirrel *Sciurus carolinensis carolinensis* (Harkema 1936; Parker and Holliman 1971) were found naturally infected, and recently in Brazil, the Ingram's squirrel *Guerlinguetus ingrami*, was reported harboring strobilocercus larvae of this cestode (Mello et al. 2018).

Previous studies in Yucatán have reported that *H. taeniaeformis* is a common parasite of synanthropic rodents (*M. musculus* and *R. rattus*) in urban and rural localities (Rodríguez-Vivas et al. 2011; Panti-May et al. 2015, 2017, 2018). The prevalence and intensity of infection in these rodents varies from 1.4 % to 28.8 % and from one to four cysts, respectively. Although there are no records in domestic and feral cats, the presence of metacercodes in synanthropic rodents suggests that cats harbor the adult stages and release cestode eggs in the external environment. The examined squirrel was found close to Ebtún village which could indicate that the source of the infection may be a domestic or feral cat instead of a wild felid. Previous studies have also reported *H. taeniaeformis*-infected squirrels in sites close to human settlements such as forest, farm houses, or cities (Dobrovolny and Harbaugh 1934; Harkema



**Figure 3.** Scanning electron micrographs of larvae of *Hydatigera taeniaeformis*. a) scolex, b) rostellum.

1936; Mello et al. 2018). *Sciurus yucatanensis* is an arboreal species but it can spend time on the ground, which may favor the ingestion of infective eggs in the external environment.

The present work represents the first record of a cestode parasitizing a squirrel species in México. Previous to our report, only 10 nematode taxa had been recorded from *Cynomys ludovicianus*, *C. mexicanus*, *Sciurus aureogaster*, *S. deppei*, and *Otospermophilus variegatus*, namely *Spirura infundibuliformis* McLeod 1933, *Subulura* sp., Oxyuridae gen. sp., *Sciurodendrium bravohollisae* Falcón-Ordaz and Lamothe-Argumedo 2006, *Syphatineria* sp., *Trichuris* sp., *Boehmiella wilsoni* Lucker 1943, *Citellina abdita* (Caballero y Caballero 1937), *Trichuris citelli* Chandler 1945, and *Rauschtineria* sp. (García-Prieto et al. 2012; Martínez-Salazar et al. 2016). This study increases to 11 the total number of helminth species known from squirrels in México.

### Acknowledgements

We thank E. Martínez for her assistance in the Colección Mastozoológica at the Universidad Autónoma de Yucatán. To B. Mendoza Garfias for SEM micrographs. We also thank D. Hernández Mena and V. Vidal Martínez for their assistance with the molecular techniques. This study was

partially funded by Project “Análisis y evaluación de los probables vectores y reservorios del virus del Ébola en México, CONACYT-251053, Proyecto Apoyado por el Fondo Sectorial de Investigación para la Educación” (SFHB). The sequence of the DNA sample was financed by the grant CONACYT No. 201441 entitled “Plataformas de observación oceanográfica, línea base, modelos de simulación y escenarios de la capacidad natural de respuesta ante derrames de gran escala en el Golfo de México”. JAPM was supported by the CONACYT - Doctoral fellowship (no. 259164).

### Literature cited

- CABALLERO Y CABALLERO, E. 1939. Algunos endoparásitos de *Rattus rattus norvegicus* y de *Rattus norvegicus albinus*, del Laboratorio de Investigaciones Médicas del Hospital General de la Ciudad de México. *Anales del Instituto de Biología, Universidad Nacional Autónoma de México* 10:285–291.
- CANTÓ, G. J., R. I. GUERRERO, A. M. OLVERA-RAMÍREZ, F. MILIÁN, J. MOSQUEDA, AND G. AGUILAR-TIPACAMÚ. 2013. Prevalence of fleas and gastrointestinal parasites in free-roaming cats in central México. *PLoS One* 8:e60744.
- CATALANO, S., K. BÂ, N. D. DIOUF, E. LÉGER, G. G. VEROCAI, AND J. P. WEBSTER. 2019. Rodents of Senegal and their role as intermediate hosts of *Hydatigera* spp. (Cestoda: Taeniidae). *Parasitology* 146:299–304.
- DOBROVOLNY, C. G., AND M. J. HARBAUGH. 1934. *Cysticercus fasciolaris* from the red squirrel. *Transactions of the American Microscopical Society* 53:67.
- GARCÍA-PRieto, L., J. FALCÓN-ORDAZ, AND C. GUZMÁN-CORNEJO. 2012. Helminth parasites of wild Mexican mammals: list of species, hosts and geographical distribution. *Zootaxa* 92:1–92.
- GUTIÉRREZ-GONZÁLEZ, J. 1980. Algunos helmintos parásitos en ratas silvestres de Apodaca, Nuevo León, México. B. S. Thesis, Universidad Autónoma de Nuevo León, México.
- HARKEMA, R. 1936. The parasites of some North Carolina rodents. *Ecological Monographs* 6:151–232.
- HERNÁNDEZ-MENA, D. I., M. GARCÍA-VARELA, AND G. PÉREZ-PONCE DE LEÓN. 2017. Filling the gaps in the classification of the Digenea Carus, 1863: systematic position of the Proterodiplostomidae Dubois, 1936 within the superfamily Diplostomoidea Poirier, 1886, inferred from nuclear and mitochondrial DNA sequences. *Systematic Parasitology* 94:833–848.
- HIERRO-HUERTA, P. 1992. Helminthofauna de la “rata de alcantarilla” *Rattus norvegicus* Erxleben, 1777, de la Ciudad de Morelia, Michoacán, México. B. S. Thesis, Universidad Michoacana de San Nicolás de Hidalgo, México.
- JONES, A., AND M. J. PYBUS. 2001. Taeniasis and echinococcosis. Pp. 150–192 in *Parasitic diseases of wild mammals* (Samuel, W. M., M. J. Pybus, and A. A. Kocan, eds.). 2nd ed. Iowa State University Press, Ames, U. S. A.
- LAVIKAINEN, A., T. IWAKI, V. HAUKISALMI, S. V. KONYAEV, M. CASIRAGHI, N. E. DOKUCHAEV, A. GALIMBERTI, A. HALAJIAN, H. HENTTONEN, M. ICHIWAKA-SEKI, T. ITAGAKI, A. V. KRIVOPALOV, S. MERI, S. MORAN, A. NÄREAHO, G. E. OLSSON, A. RIBAS, Y. TEREFE, AND M. NAKAO. 2016. Reappraisal of *Hydatigera taeniaeformis* (Batsch, 1786) (Cestoda: Taeniidae) sensu lato with description of *Hydatigera kamiyai* n. sp. *International Journal for Parasitology* 46:361–374.

- MARTÍNEZ-SALAZAR, E. A., V. FLORES-RODRÍGUEZ, R. ROSAS-VALDEZ, AND J. FALCÓN-ORDAZ. 2016. Helminths parasites of algunos roedores (Cricetidae, Heteromyidae, and Sciuridae) de Zacatecas, México. *Revista Mexicana de Biodiversidad* 87:1203–1211.
- MELLO, M. É., L. F. V. FURTADO, E. M. L. RABELO, AND H. A. PINTO. 2018. DNA barcoding of metacestodes found in the *Guerlinguetus ingrami* (Rodentia: Sciuridae) reveals the occurrence of *Hydatigera taeniaeformis* sensu stricto (Cyclophyllidea: Taeniidae) in the Americas. *Parasitology International* 67:115–118.
- PACHECO-CORONEL, N. 2010. Estudio piloto de la frecuencia de parásitos de mamíferos ferales y silvestres de la Reserva Ecológica del Pedregal de San Ángel de la UNAM. MSc. Thesis, Universidad Nacional Autónoma de México, México.
- PANTI-MAY, J. A., M. C. DIGIANI, E. E. PALOMO-ARJONA, Y. M. GURUBEL-GONZÁLEZ, G. T. NAVONE, C. MACHAIN-WILLIAMS, S. F. HERNÁNDEZ-BETANCOURT, AND M. R. ROBLES. 2018. A checklist of the helminth parasites of sympatric rodents from two Mayan villages in Yucatán, México. *Zootaxa* 4403:495–512.
- PANTI-MAY, J. A., E. PALOMO-ARJONA, Y. GURUBEL-GONZÁLEZ, M. A. TORRES-CASTRO, V. M. VIDAL-MARTÍNEZ, C. MACHAIN-WILLIAMS, S. F. HERNÁNDEZ-BETANCOURT, AND M. R. ROBLES. 2017. New host, geographical records, and factors affecting the prevalence of helminths infection from synanthropic rodents in Yucatán, México. *Helminthologia* 54:231–239.
- PANTI-MAY, J. A., S. F. HERNÁNDEZ-BETANCOURT, R. I. RODRÍGUEZ-VIVAS, AND M. R. ROBLES. 2015. Infection levels of intestinal helminths in two commensal rodent species from rural households in Yucatan, México. *Journal of Helminthology* 89:42–48.
- PARKER, J. C., AND R. B. HOLLIMAN. 1971. Observations on parasites of gray squirrels during the 1968 emigration in North Carolina. *Journal of Mammalogy* 52:437–441.
- PULIDO-FLORES, G., S. MORENO-FLORES, AND S. MONKS. 2005. Helminths of rodents (Rodentia: Muridae) from Metztlán, San Cristobal, and Rancho Santa Elena, Hidalgo, México. *Comparative Parasitology* 72:186–192.
- RAUSCH, R., AND J. D. TINER. 1948. Studies on the parasitic helminths of the North Central States. I. Helminths of Sciuridae. *American Midland Naturalist* 39:728–747.
- RODRÍGUEZ-VIVAS, R. I., J. A. PANTI-MAY, J. PARADA-LÓPEZ, S. F. HERNÁNDEZ-BETANCOURT, AND H. RUIZ-PIÑA. 2011. The occurrence of the larval cestode *Cysticercus fasciolaris* in rodent populations from the Cuxtal ecological reserve, Yucatán, México. *Journal of Helminthology* 85:458–461.

Associated editor: Jesús Fernández

Submitted: December 4, 2018; Reviewed: March 13, 2019;

Accepted: April 5, 2019; Published on line: April 28, 2019.