

# Abnormal tooth and home range size of a male tayra (*Eira barbara*) in Atlantic Rain Forest, South Brazil

## Diente anormal y ámbito hogareño de un viejo de monte (*Eira barbara*) en la Mata Atlántica al sur de Brasil

ROSANE VERA MARQUES<sup>1</sup>, ANDREA SARAHÍ FERNÁNDEZ-MONTEJO<sup>2</sup>, AND ÁLVARO JOSÉ VILLAFANE-TRUJILLO<sup>2,3\*</sup>

<sup>1</sup>Unidade de Assessoramento Ambiental, Gabinete de Assessoramento Técnico. Ministério Público do Estado do Rio Grande do Sul CEP. 90.010-210. Porto Alegre, RS, Brasil. E-mail: [rosanbat@terra.com.br](mailto:rosanbat@terra.com.br) (RVM).

<sup>2</sup>Laboratorio de Zoología, Facultad de Ciencias Naturales, Campus Juriquilla, Universidad Autónoma de Querétaro. Av. de la Ciencias s/n, Santa Rosa Jáuregui, C. P. 76230. Santiago de Querétaro, Querétaro, México. E-mail: [andy.montejo94@gmail.com](mailto:andy.montejo94@gmail.com) (ASF-M).

<sup>3</sup>Instituto de Investigaciones Biológicas, Universidad Veracruzana. Av. Luis Castelazo Ayala s/n, Col. Industrial Ánimas, C. P. 91190. Xalapa de Enríquez, Veracruz, México. E-mail: [villafanetrujillo85@gmail.com](mailto:villafanetrujillo85@gmail.com) (ÁJV-T).

\*Corresponding author

The study of dental abnormalities in mustelids has allowed identifying and describing pathologies of species distributed in different habitats and continents. These analyses have been carried out in dead animals. Through a noninvasive survey, we found a Neotropical mustelid *in situ* with a dental abnormality. We take advantage of this characteristic to obtain ecological information about the species. We describe the camera trap records of a free-living male tayra (*Eira barbara*) from South Brazil with an overdeveloped upper left canine; we used this feature to identify the specimen and recapture it individually. Through the analysis of the Kernel density estimation, we calculated his home range size. We reviewed skulls of tayra in search of dental abnormalities. The male tayra were recaptured in 5 camera stations within the Floresta Nacional de São Francisco de Paula (FLONA-SFP) on 11 different occasions during 7 months (from March to September of 2012), its home range size was 4.79 km<sup>2</sup>. We found differences in the number of molars in the mandible in two of the five skulls that we reviewed. Apparently, the abnormal canine has not interfered with the eating habits of the tayra, who has reached adulthood. This tayra could occupy an area outside our survey polygon within the FLONA-SFP; his home range size could be more extensive than we reported.

**Key words:** Carnivore; diet; diurnal; mammal; mustelid; Neotropics; omnivore; scansorial.

El estudio de anomalías dentales en mustélidos ha permitido identificar y describir patologías de especímenes distribuidos en diferentes hábitats y continentes. Estos análisis han sido implementados en cráneos de animales muertos. A través de un monitoreo no invasivo, se detectó a un mustélido neotropical *in situ* con una anomalía dental, esa característica fue aprovechada para obtener información ecológica de la especie. Se analizaron registros de cámara trampa de un cabeza de viejo (*Eira barbara*) en vida libre en el sur de Brasil, el cual presentaba un canino superior izquierdo sobre-desarrollado, esta característica permitió identificarlo individualmente y recapturarlo. Mediante la estimación de densidad de Kernel se calculó el tamaño de su ámbito hogareño. Se revisaron cráneos de la especie en busca de anomalías dentales. El espécimen fue recapturado en 5 estaciones de foto-muestreo dentro del Floresta Nacional de São Francisco de Paula (FLONA-SFP) en 11 ocasiones diferentes, durante un periodo de 7 meses (Marzo a Septiembre de 2012), el tamaño de su ámbito hogareño fue de 4.79 km<sup>2</sup>. Se encontraron diferencias en la cantidad de molares en dos mandíbulas de los cinco cráneos revisados. Aparentemente el canino anormal no ha interferido en la alimentación del espécimen, ya que ha alcanzado la adultez. El cabeza de viejo podría ocupar un área fuera de nuestro polígono de estudio dentro de la FLONA-SFP, por lo cual el tamaño de su ámbito hogareño podría ser más grande de lo que se reporta.

**Palabras clave:** Carnívoro; dieta; diurno; escansorial; mamífero; mustélido; Neotrópico; omnívoro.

© 2021 Asociación Mexicana de Mastozoología, [www.mastozoologiamexicana.org](http://www.mastozoologiamexicana.org)

The study on variations in mammals' dental characteristics (size, shape, quantity, and pathologies) provide insights related to feeding habits, evolutive history, life experience and ontogeny (Alt 1999). In mustelids the studies in dental abnormalities have been developed from the study of skulls, which has made it possible to identify pathologies in several species, such as: *Enhydra lutris* (fused teeth, and periodontitis; Winer et al. 2012), *Gulo gulo* (additional teeth – polydonty –, congenital lack of teeth – oligodonty –, and

root rotation; Jung et al. 2016), *Lutra lutra* (deviations from normal dental pattern, polydonty or oligodonty, displacement of the teeth in the tooth row and abnormal shape of teeth; Hauer 2002), *Martes foina* (irregular arrangements, polydonty, oligodonty, unilaterally or bilaterally lack of teeth, rotation, and crown fractures; Konjevi et al. 2011), *Martes martes* (size differences between tooth rows, lower incisors of different sizes, tooth twisted or partly erupted, atypical number of incisors, and overdeveloped tooth;

[Wolsan 1984](#)), *Meles meles* (numerical variations in the number of premolars; [Hancox 1988](#)), and *Neovison vison* (abnormal molars structure; [Korablev et al. 2013](#)). Here we report the first abnormal tooth record of a living tayra (*Eira barbara*) *in situ*, and the first home range size of the species obtained non-invasively.

The records are the result of camera trap surveys in Floresta Nacional de São Francisco de Paula (located in the municipality of São Francisco de Paula, within the state of Rio Grande do Sul, geographic limits of the FLONA-SFP are: 29° 23' 31.38" S, 50° 22' 55.78" W (North); 29° 27' 15.88" S, 50° 24' 9.32" W (South); 29° 26' 9.53" S, 50° 22' 4.01" W (East); and 29° 24' 48.85" S, 50° 25' 1.45" W (West); [ICMBio 2020](#)), focused on the monitoring of middle-sized and large mammals (Authorization SISBIO / ICMBio n° 26664-1). The FLONA-SFP has an extension of 1,615.6 ha; vegetation is mostly covered by a subtype of Atlantic Forest (*Mixed Ombrophilous Forest*), planted *Araucaria*, *Pinus*, and open fields, the area has rivers, lakes and swamps ([Renner et al. 2016](#)). The weather is humid, warm, temperate oceanic climate (*Cfb* Köppen-Geiger System; [Kottek et al. 2006](#)). The mean annual precipitation is 2,240 mm; temperature ranges from -6.5 °C to 34 °C, there is not a dry season ([Cademartori et al. 2002](#)).

In total 13 camera stations (each with 2 cameras) were installed for the survey of 2012. We used noncommercial camera traps triggered by infrared sensors ([Marques and Ramos 2001](#)). Each photograph included the information of date and hour. The sampling effort was 1,825 camera-days; the cameras formed a polygon of 5 km<sup>2</sup>. After recording a male tayra with a distinctive dental abnormality, we calculated his home range with the Kernel density estimation (due to the low number of captures, we selected 75th percentiles to avoid overestimation; [Worton 1989](#)). Finally, to determine if there are records of dental abnormalities in the genus *Eira*, we reviewed the skulls of other tayra specimens deposited in different Mammal Collections in México.

On March 4 of 2012 at 16:48 hr, we recorded an adult male tayra (based on the presence of the testicles, which reach full growth at 18 months old; [Poglayen-Neuwall 1975](#)) with an overdeveloped upper left canine (Figure 1).



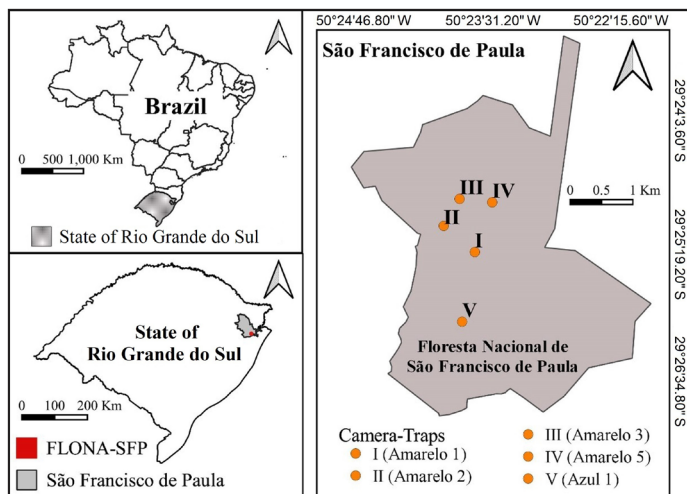
**Figure 1.** A) sagittal plane of a tayra (*Eira barbara*) skull with regular size canine (IIB-UV 3783). Capture (C) 1 to 11) Independent captures of tayra male with abnormal upper left canine. Arrow points at the distinctive feature.

Additional records obtained in May ( $n = 6$ ) of the same year allowed us to confirm this distinctive feature.

This unusual characteristic was used to individually identify this male specimen, which was recaptured on other 10 occasions in four different camera stations, from March to September 2012 (Table 1). The captures occurred mainly during the diurnal period ( $n = 6$ , 54.54 %), and in lower proportion during the crepuscular (1 hr before and after sunrise and sunset;  $n = 3$ , 27.27 %), and nocturnal ( $n = 2$ , 18.18 %) periods. According to the recaptures, the camera traps location, and the Kernel density estimation (ArcGIS version 10; ESRI 2021), the male tayra occupied a minimum area of 4.79 km<sup>2</sup> (Figure 2).

**Table 1.** Non-invasive records of the tayra (*Eira barbara*) male in Floresta Nacional de São Francisco de Paula, Brazil, through 2012. Each capture (C) is available in Figure 1.

Number of capture	Day	Month	Hour	Latitude	Longitude
C1	4	March	16:48	29° 25' 39.10" S	50° 23' 48.40" W
C2	3	May	12:50	29° 25' 23.60" S	50° 24' 6.80" W
C3	12	May	09:03	29° 25' 23.60" S	50° 24' 6.80" W
C4	20	May	17:47	29° 25' 39.10" S	50° 23' 48.40" W
C5	27	May	17:40	29° 25' 23.60" S	50° 24' 6.80" W
C6	31	May	00:30	29° 25' 23.60" S	50° 24' 6.80" W
C7	31	May	01:41	29° 25' 23.60" S	50° 24' 6.80" W
C8	2	June	07:57	29° 25' 9.70" S	50° 23' 38.10" W
C9	13	July	11:31	29° 25' 39.10" S	50° 23' 48.40" W
C10	17	August	12:32	29° 26' 20.30" S	50° 23' 55.90" W
C11	11	September	13:54	29° 25' 7.70" S	50° 23' 57.40" W



**Figure 2.** Study area at Floresta Nacional de São Francisco de Paula (FLONA-SFP), South Brazil, the symbols indicate the coordinates where the tayra (*Eira barbara*) were recorded from March to September, 2012. Roman numbers correspond to the name of each camera station.

In order to compare dental abnormalities among specimens, we reviewed 5 different skulls of tayra deposited in: Colección Mastozoológica del Centro de Estudios en Desarrollo Sustentable y Aprovechamiento de la Vida Silvestre de la Universidad Autónoma de Campeche, CEDESU-UAC,  $n = 3$ ; Colección Nacional de Mamíferos, CNMA,  $n = 1$ ; and Colección de Mamíferos del Instituto de Investigaciones Biológicas de la Universidad Veracruzana, IIB-UV,  $n = 1$ ; all these specimens were collected in México. Through a visual analysis we found differences in the number of molars in the mandible (it is not clear if it is a case of polydonty or oligodonty) in 2 (40 %) of the 5 skulls (Figure 3). This information matches with the adult dentition of the species in the literature: incisives 3/3, canines 1/1, premolars 3/3-4, and molars 1/1-2 (Presley 2000).

We do not have a supported explanation to the origin of this abnormal tooth. This could result from an irregular concentration of dental germ, or mutations in genes and proteins that affect tooth morphogenesis (Korablev et al. 2013). The physical appearance of the specimen makes us think that the abnormal canine is not an impediment to carry out their feeding habits (tayra is an opportunistic omnivore; Presley 2000). We support our statement on three facts: 1) the specimen is an adult (presence of testi-

cles confirm that); 2) the intercostal spaces are not marked, which indicates that the specimen is fed enough to be within their healthy weight rank (from 2.7 to 7 kg; Presley 2000), and 3) apparently, there is a weight fluctuation during the months of survey (in the records of May, June and August, the specimen looks heavier).

We acknowledge that the home range where this specimen was recorded is small in comparison with previous reports. However, those home range values are the results of more exhaustive surveys and radio-telemetry, which provides coverage over larger areas and constant records of the species (see Table 2). In this study the male tayra was detected only in 5 (38.46 %) of the 13 camera stations. The captures occurred mainly during the diurnal period, matching the statement that tayras exhibit diurnal habits throughout their distribution (Villafañe-Trujillo et al. 2021). Besides the abnormal canine, we observed the shape of the left side of their throat patch. Both features allowed us to individually identify this specimen (Villafañe-Trujillo et al. 2018). Probably one or more photo captures of the right side of tayras (or photos of specimens walking away from the cameras) belongs to this particular male. To our knowledge there are no impediments for the male tayra in FLONA-SFP to occupy an area outside the survey polygon (which could increase our data of home range size).

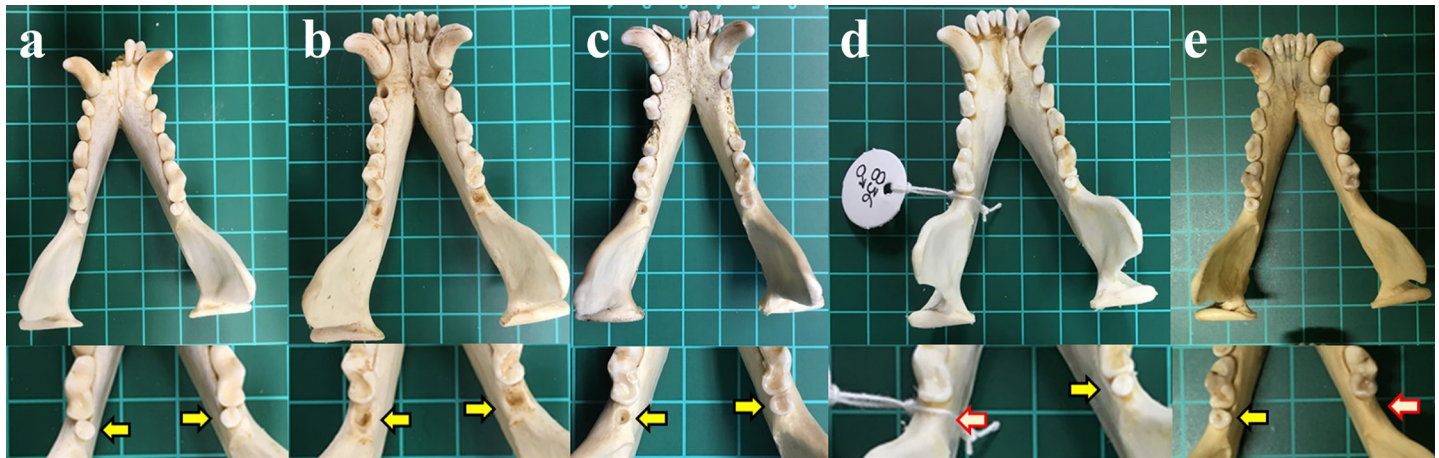
The variation in the number of inferior premolars and molars in the literature (Presley 2000), and molars that we report could indicate: 1) that tayra have a dental variation in number of teeth through their range (probably related to the phenotype), 2) that the authors consulted by Presley (2000) inadvertently reported cases of specimens with polydonty (or oligodonty), or 3) the presence of a fourth premolar and second molar are vestigial features that only manifest in some individuals. It is necessary to analyze skulls of tayra collected through the complete range of the species to identify if the variation in the number of inferior premolars and molars is frequent, and if is restricted to a geographic region, phenotype, or sex.

This is the first report of a living Neotropical mustelid with abnormal dental characteristics recorded through a non-invasive method, and the first record for *Eira barbara*. We also report for the first time the home range of the species obtained non-invasively. We encourage the

**Table 2.** Home range size of *Eira barbara* obtained through radio-telemetry.

Location	Specimen	Length of survey	Number of records	Home range size (km <sup>2</sup> )	Reference
Cockscomb Basin Forest Reserve; Belize	Male 1	3 months	20	2.11	Konecny 1989
	Male 2	10 months	95	24.44	
	Female 1	13 months	165	16.03	
Ipanema National Forest, Iperó; Brazil	Female 2	11 months	28	5.3	Michalski et al. 2006
Fondo Pecuario Masaguaral, Venezuelan llanos; Venezuela	Female	49 days	118	2.25 to nearly 9.00	Sunquist et al. 1989





**Figure 3.** Ventral views of the mandible of five specimens of *Eira barbara* collected in México. The variation in the number of molars is marked (the yellow arrows indicate the presence of a second molar; the white arrows indicates the congenital lack of a second molar). Specimens a (female; CEDESU–UAC 897), b (male; CEDESU–UAC 604), and c (undetermined sex; IIB–UV 3783) had a second molar in both tooth rows ( $n = 4$ ). Specimens d (male; CEDESU–UAC 836) and e (female; CNMA 4160) only had a second molar in one tooth row ( $n = 3$ ). The bottom of the figure shows an enlargement of each mandible.

study of skulls of tayra in Mammal Collections to develop research about variations in dental abnormalities of this species, in order to increase our knowledge of this Neotropical mustelid.

### Acknowledgements

RVM wants to thank F. de Miranda Ramos by his technical support (the assembly of the cameras) and assistance in the field. Also thank to the Staff of FLONA-SFP and Instituto Chico Mendes para la Conservación de la Biodiversidad for their effort to maintain that conservation unit. ASF-M and ÁJV-T wants to thank to A. Snyder of the Sedgwick County Zoo for her feedback regarding the teeth of captive tayras. We thank those at the Colección Mastozoológica del Centro de Estudios en Desarrollo Sustentable y Aprovechamiento de la Vida Silvestre de la Universidad Autónoma de Campeche (CEDESU-UAC), in particular O. G. Retana-Guiascón for allowed us to photograph the skulls of specimens “a”, “b” and “d” (#897, #604, and #836, respectively). We thank the Colección Nacional de Mamíferos (CNMA), in particular to F. A. Cervantes, Y. Hortelano-Moncada, and J. Vargas-Cuenca for allowed us to photograph the skull of specimen “e” (#4160). We thank those at the Colección de Mamíferos del Instituto de Investigaciones Biológicas de la Universidad Veracruzana (IIB-UV), in particular to C. A. Delfín-Alfonso for allowed us to photograph the skull of specimen “c” (#3783). We thank to C. A. López-González and M. A. Ochoa-Mendoza, and two anonymous reviewers for providing helpful comments to this document.

### Literature cited

ALT, K. W. 1999. Spuren in die Vergangenheit. *Quintessenz Team Journal* 29:685-694.

CADEMARTORI, C. V., R. V. MARQUES, S. M. PACHECO, L. R. M. BAPTISTA, AND M. GARCIA. 2002. Roedores ocorrentes em Floresta Ombrófila Mista (São Francisco de Paula, Rio Grande do Sul) e a caracterização de seu hábitat. *Comunicações do Museu de Ciências e Tecnologia PUCRS Série Zoologia* 151:61-86.

ESRI. 2021. ArcGIS v10.0 Program distributed by the author. Environmental Systems Research Institute, Inc. Redlands. California, U.S.A.

HANCOX, M. 1988. Dental anomalies in the Eurasian badger. *Journal of Zoology* 216:606-608.

HAUER, S. 2002. Population analysis of dental anomalies of otters *Lutra lutra* from eastern Germany. *Acta Theriologica* 47:339-362.

INSTITUTO CHICO MENDES DE CONSERVAÇÃO DA BIODIVERSIDADE (ICM-BIO). 2020. Plano de Manejo: Floresta Nacional de São Francisco de Paula. In: ICMBio 2021. [https://www.icmbio.gov.br/portal/images/stories/docs-planos-de-manejo/plano\\_manejo\\_flonasaofranciscodepaula2020](https://www.icmbio.gov.br/portal/images/stories/docs-planos-de-manejo/plano_manejo_flonasaofranciscodepaula2020). Accessed in 26 April, 2021.

JUNG, T. S., G. RIVEST, D. A. BLAKEBURN, E. R. HAMM, A. VAN EYK, P. M. KUKKA, AND J.-F. ROBITAILLE. 2016. Dental anomalies suggest an evolutionary trend in the dentition of wolverine (*Gulo gulo*). *Mammal Research* 61:361-366.

KONECNY, M. J. 1989. Movement Patterns and Food Habits of Four Sympatric Carnivore Species in Belize, Central America. Pp. 243-264 in *Advances in Neotropical Mammalogy* (Redford, K. H., and J. F. Eisenberg, eds.). Sandhill Crane Pr. Gainesville, U.S.A.

KONJEVI, D., V. NJEMIROVSKIJ, M. VUKOVI, A. SLAVICA, Z. JANICKI, I. SEVERIN, AND M. SINDIĆ. 2011. Variations in shape, number and position of teeth in Stone Martens from Island Habitats (Croatia) – Preliminary Results. *Natura Croatica: Periodicum Musei Historiae Naturalis Croatici* 20:215-223.

KORABLEV, P. N., M. P. KORABLEV, N. P. KORABLEV, AND I. L. TUMANOV. 2013. Odontologic anomaly in the American mink *Neovison vison* (Carnivora, Mustelidae) and possible reasons for its appearance. *Russian Journal of Developmental Biology* 44:321-325.

KOTTEK, M., J. GRIESER, C. BECK, B. RUDOLF, AND F. RUBEL. 2006. World Map of the Köppen-Geiger climate classification updated. *Meteorologische Zeitschrift* 15:259-263.

MARQUES, R. V., AND F. M. RAMOS. 2001. Identificação de mamíferos ocorrentes na Floresta Nacional de São Francisco de Paula/IBAMA, RS com a utilização de equipamento fotográfico acionado por sensores infravermelhos. *Divulgações do Museu de Ciências e Tecnologia, UBEA/PUCRS* 6:83-94.

- MICHALSKI, F., P. G. CRAWSHAW, T. G. DE OLIVEIRA, AND M. E. FA-BIÁN.** 2006. Notes on home range and habitat use of three small carnivore species in a disturbed vegetation mosaic of southeastern Brazil / Notes sur le territoire et l'utilisation de l'habitat de trois espèces de petits carnivores dans une végétation mosaïque perturbée au Sud Est du Brésil. *Mammalia* 70:1-2.
- POGLAYEN-NEUWALL, I.** 1975. Copulatory behavior, gestation and parturition of the tayra. *Zeitschrift für Säugertierkunde* 40:176-189.
- PRESLEY, S. J.** 2000. *Eira barbara*. *Mammalian Species* 636:1-6.
- RENNER, S., E. PÉRICO, AND G. SAHLÉN.** 2016. List of Odonates from the Floresta Nacional de São Francisco de Paula (FLONA - SFP), with two new distribution records for Rio Grande do Sul, Brazil. *Biota Neotropica* 16:1-7.
- SUNQUIST, M. E., F. SUNQUIST, AND D. E. DANEK.** 1989. Ecological separation in a Venezuelan llanos carnivore community. Pp. 197-232 in *Advances in Neotropical Mammalogy* (Redford, K. H., and J. F. Eisenberg, eds.). Sandhill Crane Pr. Gainesville, U.S.A.
- VILLAFANE-TRUJILLO, Á. J., C. A. LÓPEZ-GONZÁLEZ, AND J. M. KOLOWSKI.** 2018. Throat patch variation in Tayra (*Eira barbara*) and the potential for individual identification in the field. *Diversity* 10:1-23.
- VILLAFANE-TRUJILLO, Á. J., J. M. KOLOWSKI, M. V. COVE, E. P. MEDICI, B. J. HARMSEN, R. J. FOSTER, M. G. HIDALGO-MIHART, S. ESPINOSA, G. RIOS-ALVEAR, C. REYES-PUIG, J. P. REYES-PUIG, X. M. DA SILVA, A. PAVIOLO, P. CRUZ, AND C. A. LÓPEZ-GONZÁLEZ.** 2021. Activity patterns of tayra (*Eira barbara*) across their distribution. *Journal of Mammalogy* 102:772-778.
- WINER, J. N., S. M. LIONG, AND F. J. M. VERSTRAETE.** 2012. The Dental Pathology of Southern Sea Otters (*Enhydra lutris nereis*). *Journal of Comparative Pathology* 149:346-355.
- WOLSAN, M.** 1984. Dental Abnormalities in the Pine Marten *Martes martes* (L.) (Carnivora, Mustelidae) from Poland. *Zoologischer Anzeiger Jena* 213:119-127.
- WORTON, B. J.** 1989. Kernel methods for estimating the utilization distribution in home-range studies. *Ecology* 70:164-168.

Associated editor: Jesús R. Hernández-Montero

Submitted: May 27, 2021; Reviewed: October 30, 2021.

Accepted: November 15, 2021; Published on line: November 22, 2021.